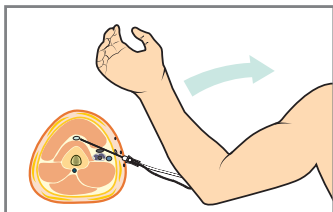
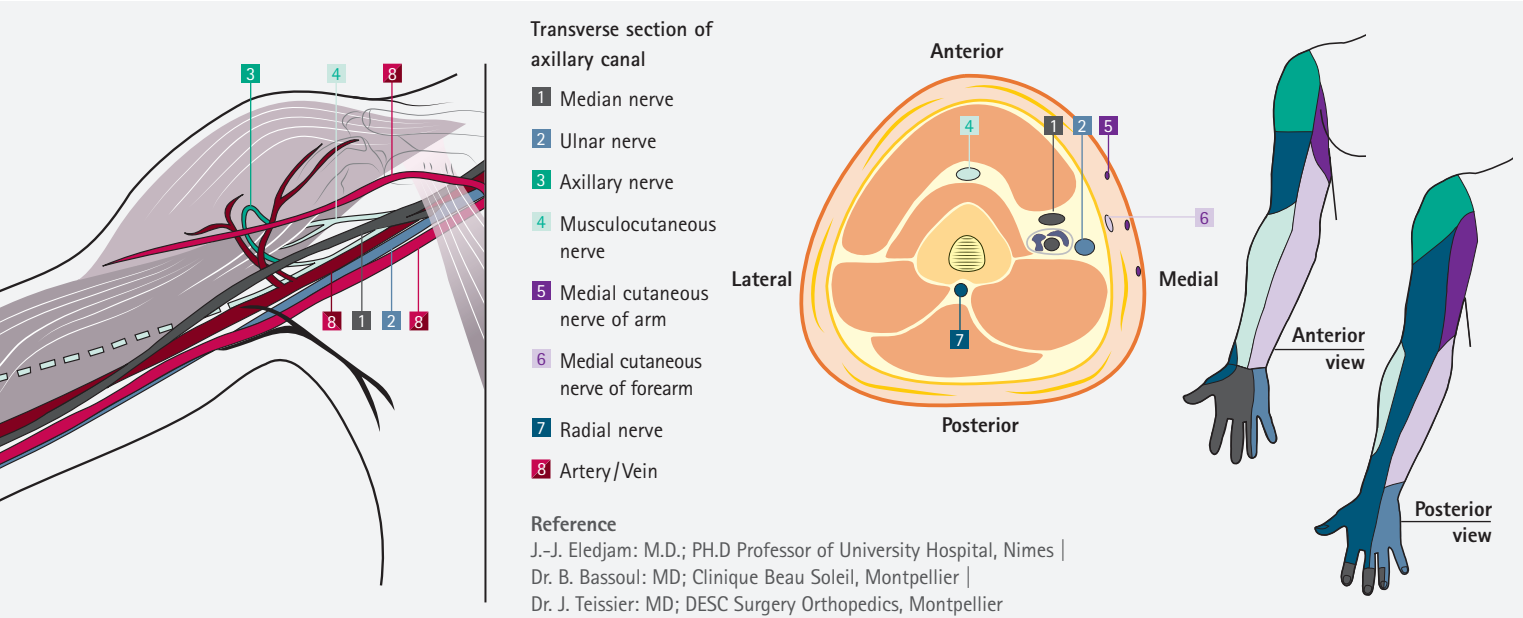
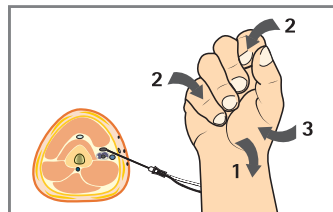


# Regional Anesthesia Upper Extremity

## Axillary approach

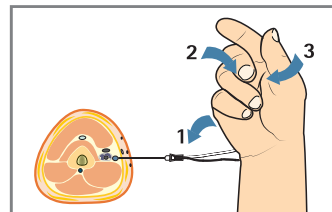


**Motor response to musculocutaneous nerve stimulation**



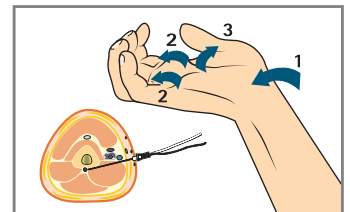
**Motor response to median nerve stimulation**

- 1 | Wrist flexion
- 2 | Fingers' flexion
- 3 | Thumb opposition



**Motor response to ulnar nerve stimulation**

- 1 | Ulnar deviation of the wrist
- 2 | Metacarpo-phalangeal flexion
- 3 | Thumb adduction



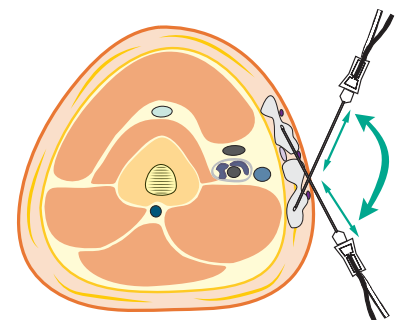
**Motor response to radial nerve stimulation**

- 1 | Wrist extension
- 2 | Metacarpo-phalangeal extension
- 3 | Thumb adduction



- 1 | Stimuplex® HNS 12
- 2 | Contiplex® S Ultra 360, Stimuplex® Ultra 360, Contiplex® Tuohy Ultra 360

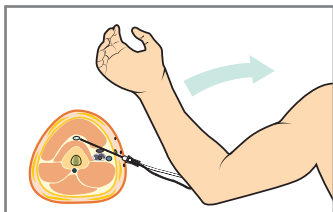
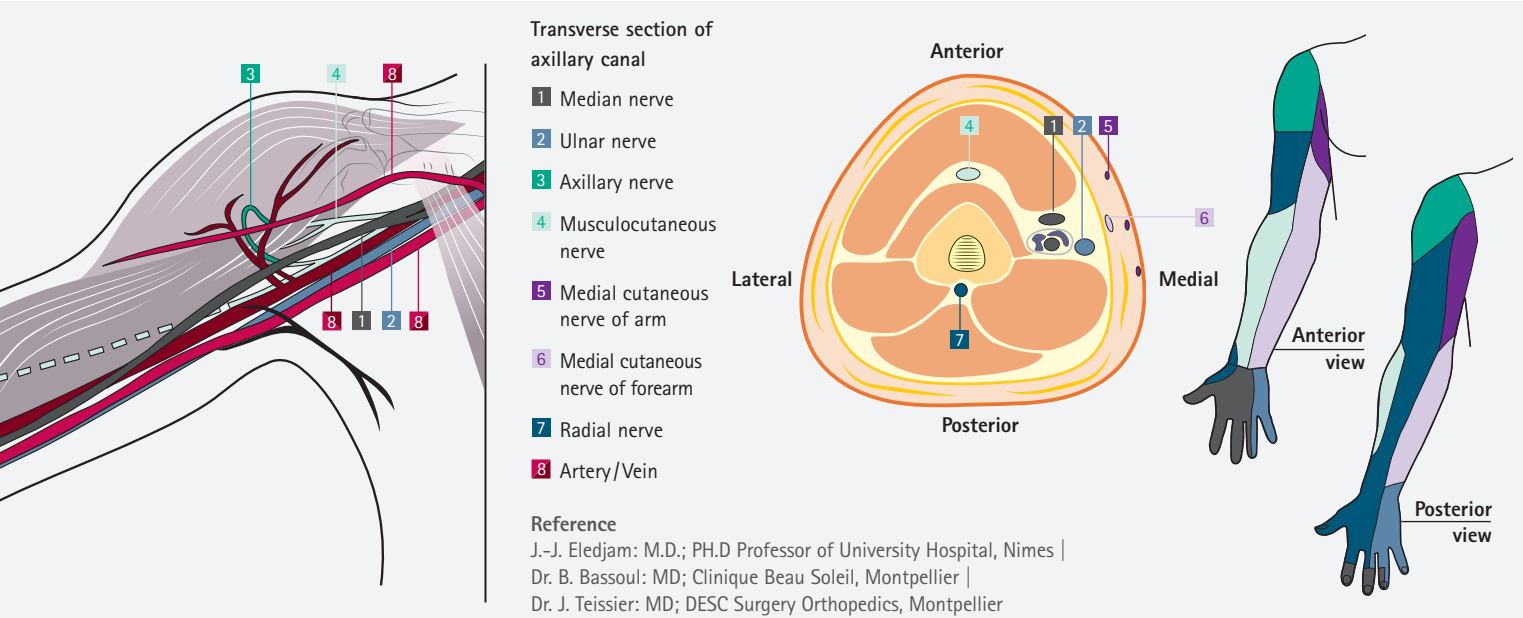
- 3 | Stimuplex® Pen
- 4 | Stimuplex® HNS compact



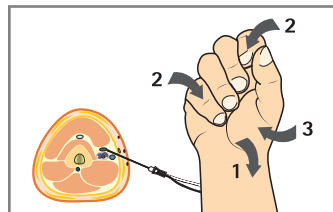
**Infiltration of the medial cutaneous nerve of the arm and the forearm**

# Regional Anesthesia Upper Extremity

## Axillary approach

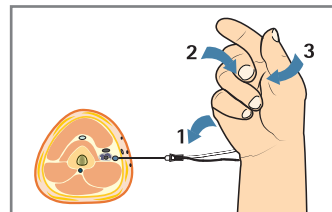


**Motor response to musculocutaneous nerve stimulation**



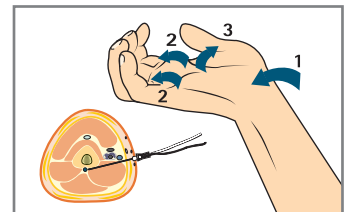
**Motor response to median nerve stimulation**

- 1 | Wrist flexion
- 2 | Fingers' flexion
- 3 | Thumb opposition



**Motor response to ulnar nerve stimulation**

- 1 | Ulnar deviation of the wrist
- 2 | Metacarpo-phalangeal flexion
- 3 | Thumb adduction

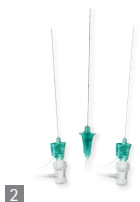

**Motor response to radial nerve stimulation**

- 1 | Wrist extension
- 2 | Metacarpo-phalangeal extension
- 3 | Thumb adduction



1



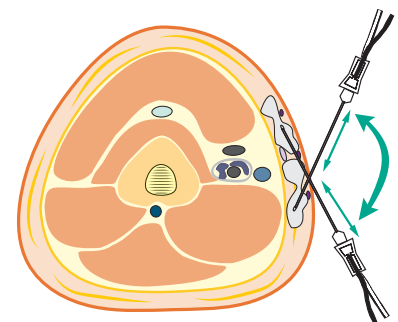
2



3

- 1 | Stimuplex® HNS 12
- 2 | Contiplex® S Ultra 360, Stimuplex® Ultra 360, Contiplex® Tuohy Ultra 360

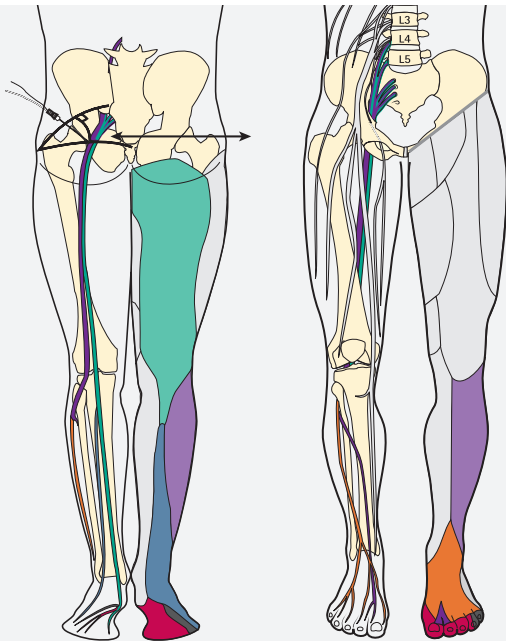
- 3 | Stimuplex® Pen



**Infiltration of the medial cutaneous nerve of the arm and the forearm**

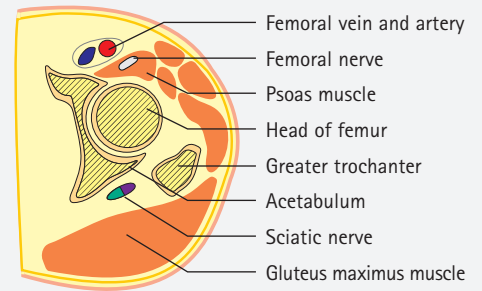
# Regional Anesthesia Lower Extremity

## Sciatic Nerve Block: Posterior Approach



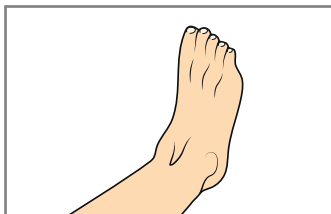
- Tibial nerve
- Posterior cutaneous nerve of thigh
- Medial plantar nerve
- Lateral plantar nerve
- Sural nerve
- Common peroneal nerve
- Lateral cutaneous nerve of calf
- Superficial peroneal nerve
- Deep peroneal nerve

Cross section of upper leg at level of head of femur

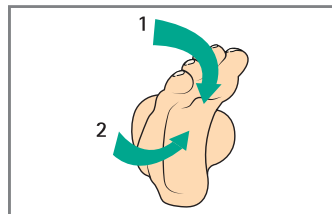


### Reference

J.-J. Eledjam: M.D.; PH.D Professor of University Hospital, Nimes |  
Dr. B. Bassoul: MD; Clinique Beau Soleil, Montpellier |  
Dr. J. Teissier: MD; DESC Surgery Orthopedics, Montpellier

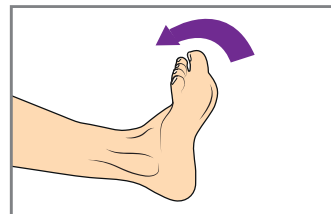


Foot in neutral position

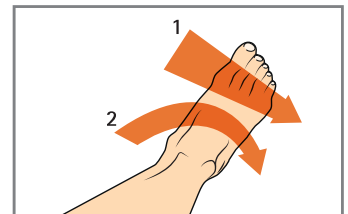


■ Motor response to tibial nerve stimulation

- 1 | Plantar flexion of foot and toes
- 2 | Inversion of foot



■ Motor response to deep peroneal nerve stimulation



■ Motor response to superficial peroneal nerve stimulation

- 1 | Abduction of foot
- 2 | Eversion of foot



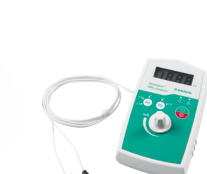1



2



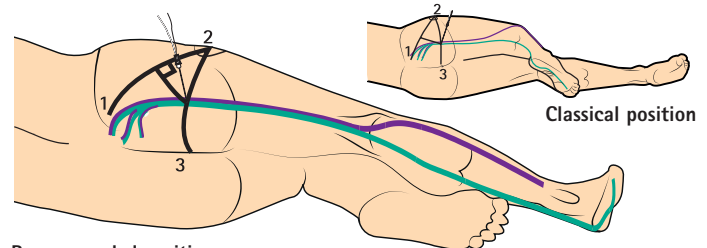
3



4

- 1 | Stimuplex® HNS 12
- 2 | Contiplex® S Ultra 360, Stimuplex® Ultra 360, Contiplex® Tuohy Ultra 360

- 3 | Stimuplex® Pen
- 4 | Stimuplex® HNS compact



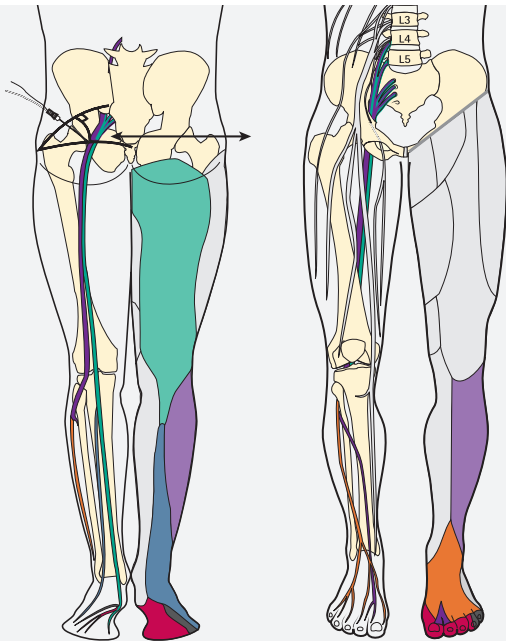
Recommended position

Classical position

- 1 | Posterior superior iliac spine
- 2 | Greater trochanter
- 3 | Sacral hiatus

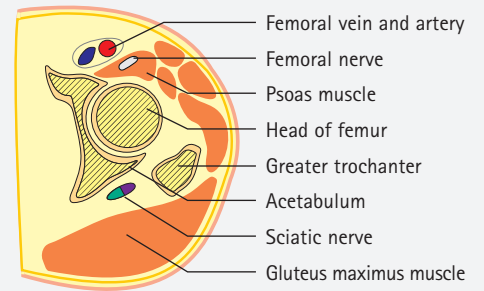

# Regional Anesthesia Lower Extremity

## Sciatic Nerve Block: Posterior Approach



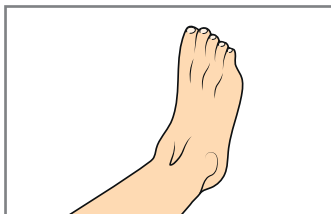
- Tibial nerve
- Posterior cutaneous nerve of thigh
- Medial plantar nerve
- Lateral plantar nerve
- Sural nerve
- Common peroneal nerve
- Lateral cutaneous nerve of calf
- Superficial peroneal nerve
- Deep peroneal nerve

Cross section of upper leg at level of head of femur

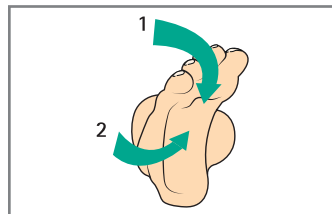


### Reference

J.-J. Eledjam: M.D.; PH.D Professor of University Hospital, Nimes |  
Dr. B. Bassoul: MD; Clinique Beau Soleil, Montpellier |  
Dr. J. Teissier: MD; DESC Surgery Orthopedics, Montpellier

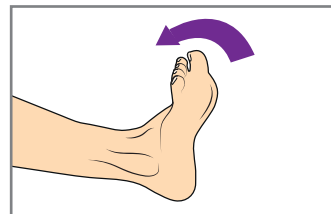


Foot in neutral position

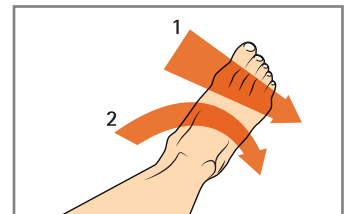


■ Motor response to tibial nerve stimulation

- 1 | Plantar flexion of foot and toes
- 2 | Inversion of foot



■ Motor response to deep peroneal nerve stimulation



■ Motor response to superficial peroneal nerve stimulation

- 1 | Abduction of foot
- 2 | Eversion of foot



1



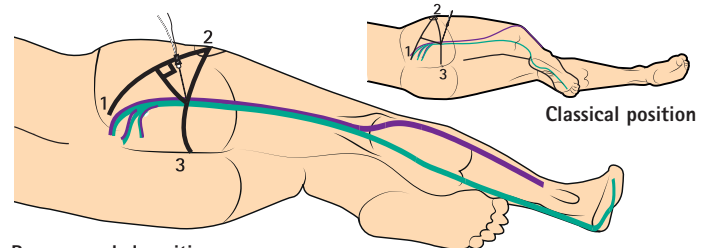
2



3

- 1 | Stimuplex® HNS 12
- 2 | Contiplex® S Ultra 360, Stimuplex® Ultra 360, Contiplex® Tuohy Ultra 360

- 3 | Stimuplex® Pen



Recommended position

- 1 | Posterior superior iliac spine
- 2 | Greater trochanter
- 3 | Sacral hiatus